



PRESENTING CLINICAL SIGNS

DATE History: Soft left apical murmur. Asymptomatic. Pre-anesthetic evaluation (neuter).

11/28/22

ECHOCARDIOGRAPHIC FINDINGS

2D, M-mode, and Doppler study.

PERFORMED BY:

Dr. Meredith Swart

Left atrial size is normal. The mitral valve appears normal. Left ventricular wall thickness is normal. Left ventricular internal dimensions are normal. Left ventricular systolic function is normal. The aorta and aortic valve are normal. Right atrial and right ventricular dimensions are normal. The tricuspid valve appears normal. The pulmonary artery and pulmonic valve are normal. No shunting lesions are visualized. No pericardial effusion or cardiac masses are seen.

INTERPRETED BY

Keith Blass, DVM,
MS, DACVIM
(Cardiology)

LA – 19.4 mm
IVSd – 5.0 mm
LVPWd – 4.9 mm
LVIDd – 20.5 mm
LVIDs – 12.6 mm
FS – 38.5%
RA – 11.1 mm
LVOT – 1.09 m/s
RVOT – 1.17 m/s

PATIENT

Barley Williams

SPECIES

Canine

ASSESSMENT/RECOMMENDATIONS

This examination demonstrates no evidence of structural heart disease. While a definitive reason for Barley's murmur was not identified, any possible flow abnormality that could be present would have minimal hemodynamic effects, as Barley does not have secondary dilation or hypertrophy of any of his cardiac chambers.

BREED

Havanese Mix

Barley's cardiovascular risk for general anesthesia is low based on this exam, and there are no contraindications to the use of any specific anesthetic agents.

SEX

No therapy is recommended based on this exam.

MI

A recheck echocardiogram is recommended if the characteristics of Barley's murmur change, or if other new physical exam and/or clinical abnormalities suggestive of cardiac dysfunction develop.

AGE

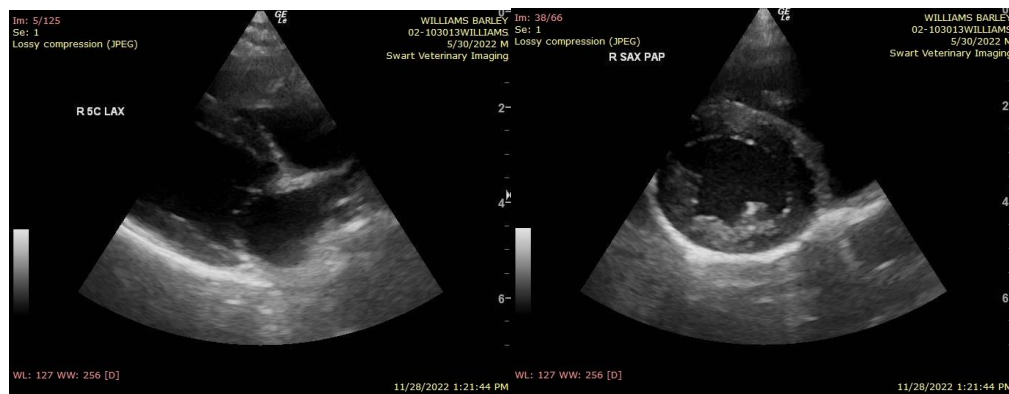5 mo

WEIGHT

10.6 lb

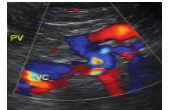
HOSPITAL NAME

Swart Veterinary
Imaging



REFERRING VET

Dr. Swart



DATE

11/28/22

The information and recommendations provided are based on the images presented by the referring veterinarian. No evaluation can be communicated regarding pathology that was not visible in the image/video clips provided.

Thank you for this referral. If the clinical or image interpretation does not parallel your findings or if I can be of any further assistance please contact me.

PERFORMED BY:

Dr. Meredith Swart

Keith Blass, DVM, MS, DACVIM (Cardiology)
KeithBlass@gmail.com
631-804-5754

INTERPRETED BY

Keith Blass, DVM,
MS, DACVIM
(Cardiology)

PATIENT

Barley Williams

SPECIES

Canine

BREED

Havanese Mix

SEX

MI

AGE

5 mo

WEIGHT

10.6 lb

HOSPITAL NAME

Swart Veterinary
Imaging

REFERRING VET

Dr. Swart